



PREVALENCE OF *SARCOCYSTOSIS* IN GOATS (*CAPRA HIRCUS*) AT WASIT PROVINCE, IRAQ

Toqa Najem Al-Waely and Amer Murhum Abd AL-Amery

Department of Parasitology, College of Veterinary Medicine, University of Baghdad, Iraq.

Abstract

This study was performed to investigate the prevalence of *Sarcocystis* in goats at Wasit province, Iraq, and include study the effect of age, sex, months, and the rejoin on the infection rate by examination of 180 muscle samples collected during the period from the beginning of October 2019 to the end of March 2020. All muscle samples were examined by traditional microscopic examination (Slide squash method, Muscle Mincing Method, Pepsin Digestion test, and stained by using Giemsa stain). Both macroscopic and microscopic cysts were recognized, the total infection rate of the macroscopic examination was 14.44% and the rate of microscopic infection was 85.55%. The infection rate of *Sarcocystis* was varied between diagnostic methods and organs the results showed that there is no significant difference, whereas the results showed that there is a highly significant difference of *Sarcocystis* infection in goats according to age at ($P \leq 0.01$) 100% (41/41) recorded in the age group 1-2 years old and 100% (9/9) recorded in age group > 7 years old while the lowest 80% (104/130) was recorded in the age $< one$ year. With a highly significant difference at ($P_d \leq 0.01$), concerning sex, there was significantly different at ($P \leq 0.05$) between female 93.42% (71/76) and male 79.80% (83/104). According to the months, the highest infection rate was demonstrated in November as 93% (28/30) compared with March as 73.33% (22/30) that showed a highly significant difference at ($P \leq 0.01$). Regions of Waist province including (Jassan, Badrah, AL-Kut city, AL-Souira, and AL-Dabouni) showed a highly significant difference at ($P_d \leq 0.01$) with infection rates ranged between (75% - 100%).

Key words : *Sarcocystis*, prevalence, pepsin digestion, goat, Iraq.

Introduction

Sarcocystosis is a silent zoonotic parasitic disease caused by an obligatory intracellular coccidian protozoan of the genus *Sarcocystis* (Prakas *et al.*, 2020).

Sarcocystis have an obligatory two-host life cycle; requires two separate hosts: a definitive host (in which the sexual stage develops, by producing oocyst/sporocysts in the intestine mucosa of carnivores predator) and an intermediate host (they reproduce asexually forming sarcocysts in the vascular endothelial and striated muscle cells of herbivores prey and omnivores) Omnivores, such as humans serve as both intermediate and definitive hosts (Hoeve-Bakker *et al.*, 2019). The multiplication within striated muscle cells leads to the formation of mature sarcocysts, which have a characteristic morphology (size, shape, and surface structure) for each species, and by which, definitive hosts become infected through ingestion of infected muscle tissue. (Gjerde *et al.*, 2020)

Sarcocystis spp. is a substantial economic zoonotic

disease involving an individual host that may harbor more than one species of *Sarcocystis*. In goat, *Sarcocystis hircicanis*, *Sarcocystis capracanis*; which produce microscopic sarcocysts that are transmitted by canids and wild predator while *Sarcocystis moulei* (*S. caprifelis*) produces macroscopic cysts transmitted by felids. (Olias *et al.*, 2010) besides, the *Sarcocystis* species that are transmitted via canids or primates are more pathogenic than those transmitted by felids ((Dafedar *et al.*, 2008).

Sarcocystis are generally nonpathogenic for the definitive host, several *Sarcocystis* species can cause many severe symptoms in intermediate hosts, like fever, weakness, inappetence, anemia, weight loss, pyrexia, hair loss, hemorrhagic diathesis, and encephalitis while in acute infections of prenatal females with *Sarcocystis* would bring about fetal death, abortion, and premature labor and the muscles were full of gaps with widely separated fibers Thus *Sarcocystosis* would cause inedible meat, and massive economic loss further (Ren *et al.*, 2019).

The aim of this study to investigate the prevalence of *Sarcocystosis* in goats (*Capra hircus*) by using macro and microscopic examination in Wasit province, Iraq and Study the effect of some factors like age, sex months and rejoin on the prevalence rate.

Materials and Methods

Animals and study period

One hundred and eighty slaughtered goats (*C. hircus*) collected randomly in Wasit from five distinct regions at Wasit province. During the period from the beginning of October 2019 to the end of March 2020. The tissue samples of 180 esophagi and 180 diaphragms were collected, the age group was < 1year into >7 years. All information's about age, sex, and date of sampling collecting were recorded and transported in refrigerator bags to the parasitology laboratory in the college of Veterinary Medicine-University of Baghdad.

Laboratory examination

A. Macroscopic examination

Macroscopic *Sarcocystis* in the collected samples esophagus and the diaphragm were detected by naked eyes in both abattoir and the Parasitological Lab. However, visual inspection was not always sufficiently sensitive in case of low infection density or cysts that did not reach its full size.

B. Microscopic examination

Detection of microscopic *Sarcocystis* involved three traditional diagnostic laboratory tests:

Trichinoscopy (Slide squash method): were prepared according to (Castroforero *et al.*, 2020).

Squeezing (Muscle Mincing Method): by using garlic press (3-5) gram from each sample putted were prepared according to (Al-Saadi and Muhammed, 2020).

Pepsin Digestion Test

About 20 g from each muscle sample was crushed and digested in 50 ml of digestion fluid (pepsin 1.3 gm, 2.5 gm NaCl, and 3.5 ml HCl dissolving in 500 ml of distilled water). These samples were incubated for 30 min. at 40 °C than filtered through gauze and centrifuged at 25000 / min. sediments were smeared on slides and staining by Giemsa stain followed by microscopic examination (100 X) (Anvari *et al.*, 2020)

Statistical Analysis

The Statistical Analysis System-SAS (2012) program was used to detect the effect of different factors in study percentages such as months of study on prevalence, a region of study, age, and sex. Chi-square test was used

to significant compare between percentage (0.05 and 0.01 probability) SAS, (2012).

Results and Discussion

Macroscopic examination

The results of this study determined that after investigative esophageal and diaphragm muscular tissue samples, the goat had been infected with both macroscopic and microscopic cysts for infection with the macroscopic form of the parasite, macroscopic examination in the esophagus and diaphragm showed an oval or cylindrical macro and micro cyst similar to milky white rice grain size buried in the muscle fibers. It was found that among the total of (N=180) examined goat by the naked eye, there was (n=26, 14.44 %) (Table 1) the result of this research agreement and relative to (Shekarforoush *et al.*, 2005; Mahran, 2009; Kargar Jahromi *et al.*, 2017) Maybe the reason for the high incidence of macroscopic infection in our study is due to the number of examined animals compared to the rest of other studies or to the large number of cats that act as final hosts or to the older ages of examined animals while this percentage disagreed with (Barham, 1992; Mala and Baranova, 1995; Dehaghi *et al.*, 2011) were reported highly macroscopic cysts 33.6%, 29.6 % and 20.74% of examined goats, respectively. Two types of macrocysts of *Sarcocystis* were isolated from goats are the fat type (macro) with rounded ends and the thin type (micro) were small, slender, and more frequent than the fat cysts. The highest incidence was in the esophagus (1.66% fat cyst and 11.66 % thin cyst), while low visible lesion seen in the diaphragm (0.55% fat cyst and 0.55% thin cyst) at range (6.8×2.6) mm in the esophagus and the diaphragm recorded (2.2×1.7) mm and (1.1×0.5) mm for the fat and the thin cyst respectively, There was a variation in the percentage of macroscopic infection between the organs, it was found that the percentage of infection in the esophagus was higher reached 13.3% (24/180) while in the diaphragm 1.1% (2/180) (Table1). This percentage was degree with (Barham, 1992; Shekarforoush *et al.*, 2005; Al-Hoot *et al.*, 2005; KargarJahromi *et al.*, 2017). That recorded high macroscopic infection in esophagus than diaphragm in slaughtered goats, It differs and disagrees from what (Abo-Shehada, 1996) that found high macroscopic infection in diaphragm rather than the esophagus.

Microscopic examination

The results showed that the percentage of microscopic infection was 85.55%, 156 samples positive out of 180 samples and this result agree with Abdulrahman and Al-Manyawe (2010), which indicate the prevalence of

Table 1: Prevalence of *Sarcocystis* in goat by using the macroscopic examination.

No. of examined animal	No. of positive cases by macroscopic examination	No. of fat cyst cases in the esophagus	No. of thin cyst cases in the esophagus	No. of fat cyst cases in the diaphragm	No. of thin cyst cases in the diaphragm	Total Percentage %
180	26	3	21	1	1	14.44

Table 2: The comparison between diagnostic methods used for diagnosis *Sarcocystis* in goat.

Organ	Pepsin digestion	Squeezing	Trichinoscopy
Esophagus	85.55% (154/180)	77.77 (140/180)	71.11% (128/180)
Diaphragm	84.44% (152/180)	75.00% (135/180)	68.88% (124/180)
Chi-Square (χ^2)	0.329 NS	0.840 NS	0.872 NS

NS: Non-Significant.

Table 3: Infection rate of *Sarcocystis* in goat according to age.

Age	Number of examined animals	Number of positive cases	Percentage % of case
< one year	130	104	80
1-2 year	41	41	100
> 7 years	9	9	100
Total	180	154	85.55
Chi-Square (χ^2)	7.300 **

HS: high significant difference ($P \leq 0.01$).**Table 4:** Infection rate of *Sarcocystis* in goat according to sex.

Sexes	Number of examined animals	Number of positive cases	Percentage % of case
Males	104	83	79.80
Females	76	71	93.42
Total	180	154	85.55
Chi-Square (χ^2)	5.027 *

S: Significant difference ($P \leq 0.05$).**Table 5:** Infection rate of *sarcocystis* in goat According to the Months.

Duration (month)	Number of examined animals	Number of positive cases	Percentage % of case
October/2019	30	24	80.00
November	30	28	93.33
December	30	27	90.00
January/2020	30	26	86.66
February	30	27	90.00
March	30	22	73.33
Total	180	154	85.55
Chi-Square (χ^2)	8.226 **

HS: high significant difference ($P \leq 0.01$).

microscopic cyst in Egypt slaughtered goats was 84.8% and agree with Mahran (2009), who recorded microscopic infection with *Sarcocystosis* in goat was 80.33% moreover agree with (Hu *et al.*, 2016) show the Prevalence in domestic goats from Kunming, China at 77.3%. The study showed the presence of several forms of microscopic cyst, including

spindle, circular, elliptical, cylindrical and twisted form in diaphragm and esophagus, the dimensions were recorded in esophagus (121.2-28.1×17.2-3.6) μm with different measurement range (71.6 × 9.5) μm and in the diaphragm (111.8-34.76×15.42-4.9) μm (10X) (Figure 2), and this agreement with Al – Hasnawi (2008), that recorded the dimension in goat (142.5-28.5×168-104) μm at range (68×59) μm .

Results have been shown different rates of laboratory tests between the three diagnostic methods and showed that there is no significant difference (Table 2). According to the type of test, the highest incidence of pepsin digestion was recorded at 85.55% in the esophagus and 84.44% in the diaphragm which considered as an excellent standard test and the most accurate and efficient method to diagnoses the microscopic sarcocysts and this came to agree and slightly relative with Barham, (1992) recorded 97.4% and Dehaghi *et al.*, (2011) 98.97% and Shekarforoush *et al.*, (2005) 100% and disagree with Rasouli *et al.*, (2006) 53.47% in goats as the intermediate host.

There is a direct relationship between the age of the animal and the percentage of microscopic infection, a high rate of infection 100% (41/41) recorded in the age group 1-2 years old and 100% (9/9) recorded in age group > 7 years old while the lowest 80% (104/130) was recorded in the age < one year (Table 3). The data analysis indicated that there is a highly statistically significant difference between age groups at ($P \leq 0.01$), which agreement with (Shekarforoush *et al.*, 2005; Rasouli *et al.*, 2006) they were studying on goats as an intermediate host appear that the infection rate increased within the age.

The present study, the infection rate of *Sarcocystosis* appear highly in females

Table 6: Infection rate of *sarcocystis* in goat according to regions.

Region	Number of examined animals	Number of positive cases	Infection rate %
Jassan	118	100	84.74
Badrah	28	24	85.71
AL-Kut city	16	14	87.50
AL-Souira	10	10	100
AL-Dabouni	8	6	75.00
Total	180	154	85.55
Chi-Square (χ^2)	8.973 **

HS: high significant difference ($P \leq 0.01$).

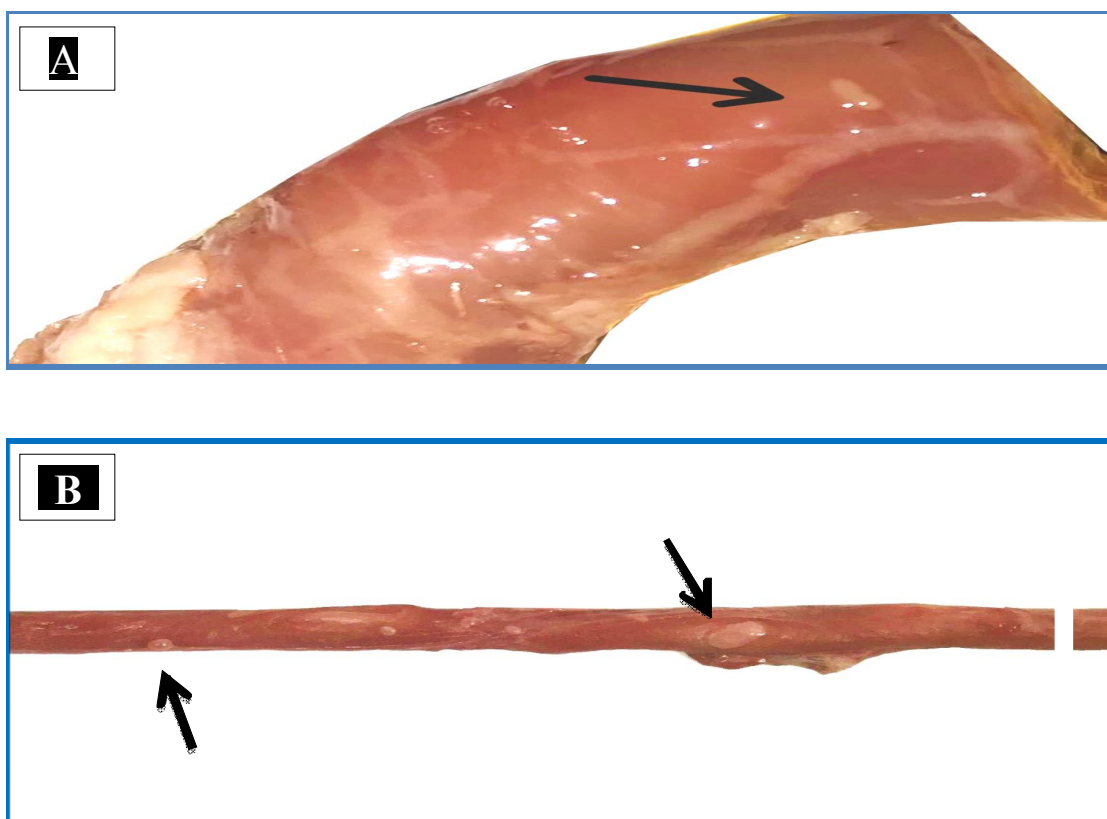


Fig. 1: Gross appearance of *Sarcocystis* in esophagus muscles of goat
 A: Esophageal muscle with white oval thin (micro) cyst of *Sarcocystis*,
 B: Esophageal muscle with white oval fat (macro) multifocal cysts.

at 93.42% while in the males was 79.80% with significant difference between male and female at the level of $P \leq 0.05$ (Table 4). This agrees with (Okita *et al.*, 2017) the infection related to sex showed that females had higher (83.33%) rate than males (16.67%), also agree with (Elbadre *et al.*, 2014) recorded that the relationship to sex was a high percentage in females than males.

The results showed that microscopic infection occurs in all seasons of the year in goats (Table 5). The epidemiology of the infection will be greatly affected by the capacity of the sporocysts to survive for long periods under possibly harsh environmental conditions. In all

situations, the sporocysts must rely on their ability to survive to ensure the completion of the life cycle. (Savini *et al.*, 1996) show that sporocysts can remain viable for long periods after being exposed to high temperatures and low relative humidities. Also, the large numbers of sporocyst that are discarded from dogs that act as final hosts, the highest infection rate in this study were demonstrated in November (93.33%) compared to March (73.33%) with a highly significant difference at level ($P \leq 0.01$).

The study showed a significant difference in prevalence *sarcocystis* among different areas in Wasit




Fig. 2: The micro cyst of *Sarcocystis* spp. by trichinoscopy method it showed esophagus cyst at (10 X). The septa dividing the internal compartments are seen as dark structures.

Province ($P \leq 0.01$) (Table 6). The highest rate was recorded in AL-Souira 9(100%), and the lowest rate in AL-Dabouni 6(75%). This variation depends on methods of animal farming and management, feeding in the open farmyard, the difference in the number of samples, the number of canine and feline predators and wild animals, contamination the feed and soil with sporocysts, house fly and cockroaches plays an important role in the mechanical transmission of *Sarcocystis*.

References

- Abdel-Rahman, M.A.M., M. Sohoir and E.L. Manyawe (2010). Identification of *Sarcocystis* species infecting goats in Egypt. *Eastern Virginia Medical School Journal*, **6**: 65-74.
- Abo-Shehada, M.N. (1996). Age variations in the prevalence of *sarcocystosis* in sheep and goats from northern and central Jordan. *Preventive Veterinary Medicine journal*, **27(3-4)**: 135-140.
- AL-Hasnawy, M.H. (2008). Epidemiological study of Ovine and Caprine *Sarcocystosis* in Babylon Province. M.Sc. Thesis College of Veterinary Medicine University of Baghdad, Iraq
- Al-Hoot, A.S., S.A. Al-Qureishy, K. Al-Rashid and A.R. Bashtar (2005). Microscopic study on *Sarcocystis moulei* from sheep and goats in Saudi Arabia. *Journal of the Egyptian Society of Parasitology*, **35(1)**: 295-312.
- Al-Saadi, S.A., K.A. Al-Mussawi and H.A. Muhammed (2020). Molecular Identification of *Sarcocystis* Species Infection in Sheep in Karbala Governorate-Iraq. *Medico Legal Update journal*, **20(1)**: 889-895.
- Anvari, D., E. Narouei, M. Hosseini, M.R. Narouei, A. Daryani, S.A. Shariatzadeh and R. Saberi (2020). *Sarcocystosis* in Ruminants of Iran, as Neglected Food-Borne Disease: A Systematic Review and Meta-analysis. *Acta Parasitologica journal*, 1-14.
- Barham, S.M. (1992). Epidemiological study of *Sarcocystosis* in goats in al sulaymaniyah city, M.Sc. Thesis College of Veterinary Medicine University of Baghdad, Iraq
- Castro-Forero, S.P., D.M. Bulla-Castañeda, H. López, A.D.A. Buitrago and L.M. De Carvalho (2020). *Sarcocystis* Spp., A Parasite With Zoonotic Potential. *Advances in Animal and Veterinary Sciences journal*, **3(9)**: 473-477.
- Dafedar, A.M., P.E. D'Souza and G.C. Puttalakshamma (2008). Prevalence of *Sarcocystosis* in goats slaughtered at an abattoir in Bangalore, Karnataka state. *Veterinary World Journal*, **1(11)**: 335.
- Dehaghi, M.M., S. Fathi and E.N. Asl (2011). Survey of *Sarcocystis* infection in slaughtered goats in Kerman Abattoir, Southeast of Iran. *Journal of Animal and Veterinary Advances*, **10(9)**: 1205-1208.
- Elbadri, M., F.A. Osman and S.M. Hussein (2014). Studies On *Sarcocystis* In Sheep And Goats Using Serological Survey In New Valley Governorate Egypt. *Journal of Medicinal Chemistry*, **5**: 50-153.
- Gjerde, B., C. De la Fuente, J.M. Alunda and M. Luzón (2020). Molecular characterisation of five *Sarcocystis* species in domestic sheep (*Ovis aries*) from Spain. *Parasitology Research Journal*, **119(1)**: 215-231.
- Hoeve-Bakker, B.J.A., J.W.B. van der Giessen and F.F.J. Franssen (2019). Molecular identification targeting *cox1* and *18S* genes confirms the high prevalence of *Sarcocystis* spp. in cattle in the Netherlands. *International journal for parasitology*, **49(11)**: 859-866.
- Hu, J.J., T. Liu, Q. Liu, W. Esch, J.Q. Chen, S. Huang and T. Wen (2016). Prevalence, morphology, and molecular characteristics of *Sarcocystis* spp. in domestic goats (*Capra hircus*) from Kunming, China. *Parasitology research Journal*, **115(10)**: 3973-3981.
- KargarJahromi, Z., K. Solhjoo, M. ZareianJahromi, H. KargarJahromi, S. Erfaniyan and M. Esmi (2012). Investigation of *Sarcocystis* infection in slaughtered goats in Jahrom Abattoir. *Journal of Fasa University of Medical Sciences*, **2(3)**: 163-167.

- Olias, P., L. Olias, M. Lierz, H. Mehlhorn and A.D. Gruber (2010). *Sarcocystis calchasi* is distinct to *Sarcocystis columbae* sp. nov. from the wood pigeon (*Columba palumbus*) and *Sarcocystis* sp. from the sparrowhawk (*Accipiter nisus*). *Veterinary parasitology Journal*, **171(1-2)**: 7-14.
- Mala, P. and M. Baranova (1995). Diagnosis of *Sarcocystis* infection in slaughter animals at veterinary meat inspection. *Veterinari Medicina journal*, **40**: 97-100.
- Mahran, O.M. (2009). *Sarcocystis* infection in sheep and goats slaughtered in Shalatin Abattoir, Red Sea Governorate, Egypt. *Assiut Veterinary Medical Journal*, **55(121)**: 341-355.
- Okita, F.O., H.I. Obadijah, K.T. Gyegweh, A.A. Okonkwo and J.A. Azatyom (2017). Survey of *Sarcocystis* species infection in slaughtered goats in Makurdi metropolis. *The International Journal of Infectious Diseases*, **2(1)**: 4-8.
- Prakas, P., D. Butkauskas and E. Juozaitytė-Ngugu (2020). Molecular identification of four *Sarcocystis* species in the herring gull, *Larus argentatus*, from Lithuania. *Parasites a Vectors Journal*, **13(1)**: 1-6.
- Ren, M., F. Wu, Y. Zou, Y. Tu, D. Wang, L.Y. Li and Q. Lin (2019). Molecular characterization of *Sarcocystis* species isolated from Chinese buffaloes in Guizhou province based on *18S rRNA* and *cox 1* sequence. *Mitochondrial DNA Part B*, **4(1)**: 637-641.
- Rassouli, S., M. Nasiri, S. Pashayan and H. Ahari (2006). *Sarcocystosis* in slaughtered animals examined by digestive method. *Journal of Comparative Pathology*, **3**: 667-670.
- Savini, G., I.D. Robertson and J.D. Dunsmore (1996). Viability of the sporocysts of *Sarcocystis cruzi* after exposure to different temperatures and relative humidities. *Veterinary parasitology Journal*, **67(3-4)**: 153-160.
- Shekarforoush, S.S., S.M. Razavi, S.A. Dehghan and K. Sarihi (2005). Prevalence of *Sarcocystis* species in slaughtered goats in Shiraz, Iran. *The Veterinary Record journal*, **156(13)**: 418.